

Unmet Medical Need: More Sensitive Image Acquisition and Analysis of Treatment Responses in Patients with Cancer

CT: The Need for Quantitative Imaging in Patients with Cancer

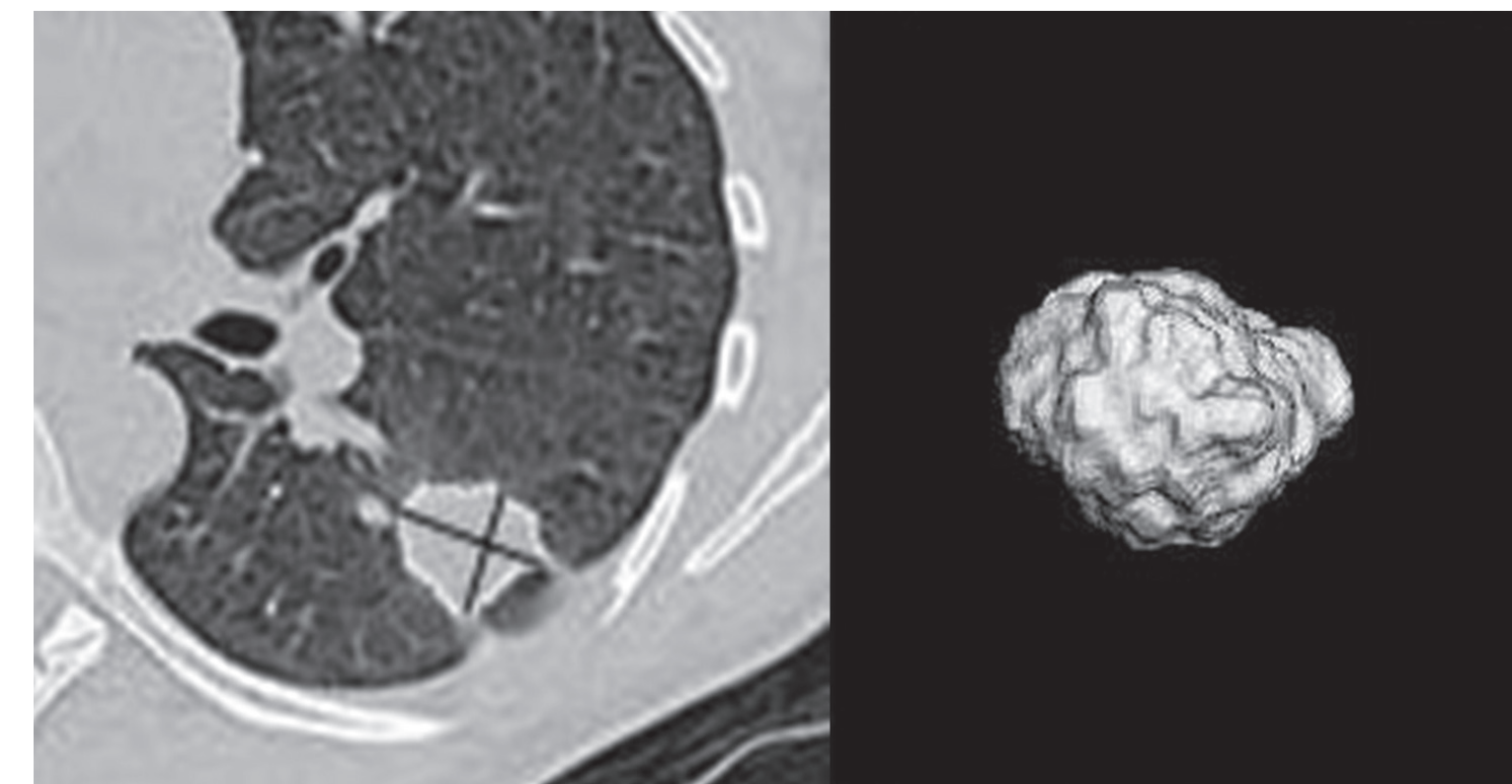
- Sensitive biomarkers of response to therapy are needed to make earlier assessments of response in the care of individual patients with cancer, as well as accelerate the development of new treatments.
- There is strong evidence that quantitative CT image analysis including volumetrics is helpful both to the individual patient and in a clinical trial.
- Volumetric image analysis appears to be a substantially more sensitive technique for detecting longitudinal changes in tumor masses than unidimensional measurements, however, this has not yet been proven. Therefore, additional studies and data need to be collected to validate volumetric CT as a biomarker for new therapies and for individual patients.
- The extraction of other features, such as density, homogeneity of density, morphology, and the like, promises to be of value in multiple therapeutic areas.

Acknowledgments

Courtesy of Professor Lawrence H. Schwartz and Professor Binsheng Zhao

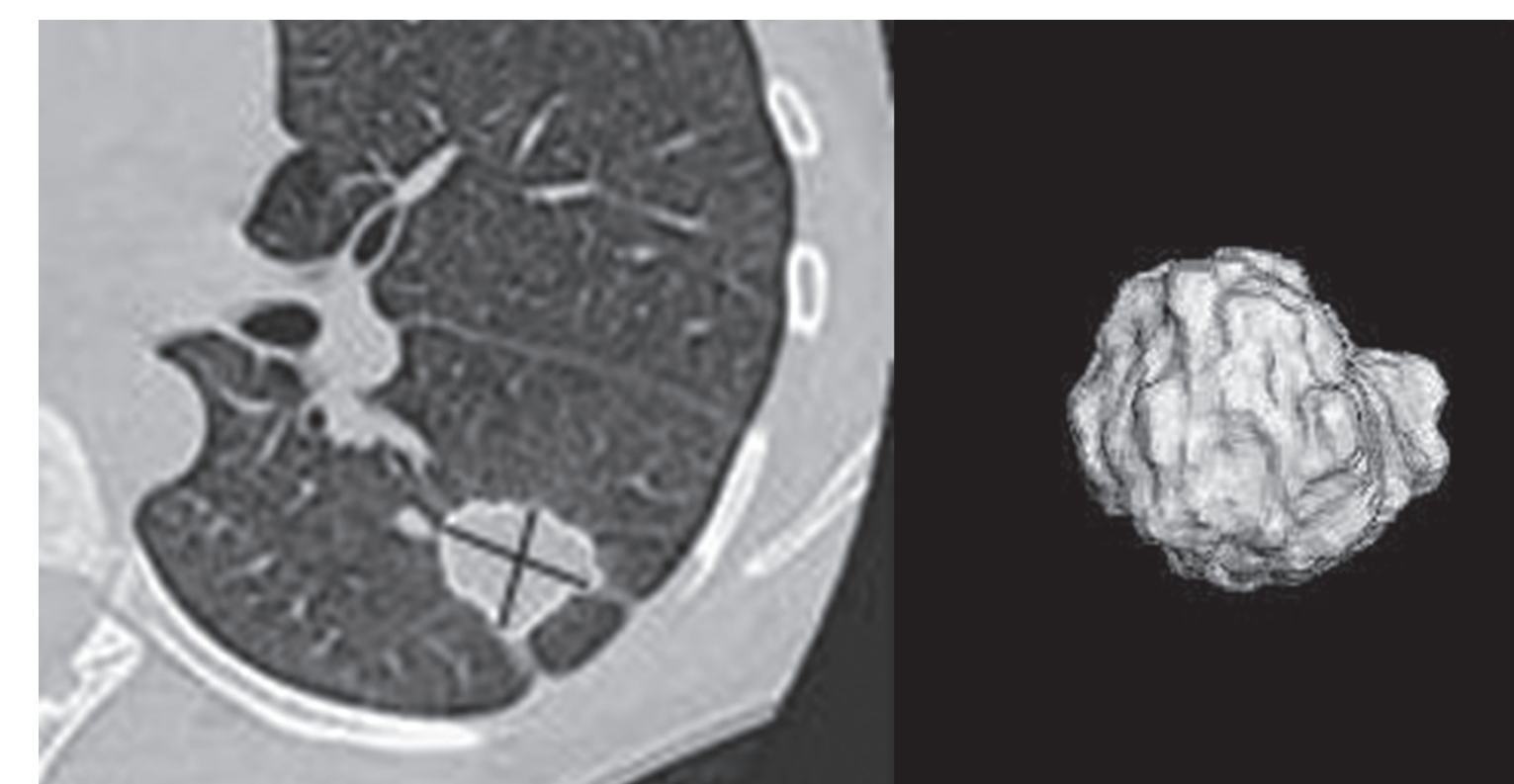
Volume Change

Pre Therapy



Long axis = 25.0 mm
Short axis = 20.4 mm
Volume = 3420 mm³

Post Therapy – 24 days



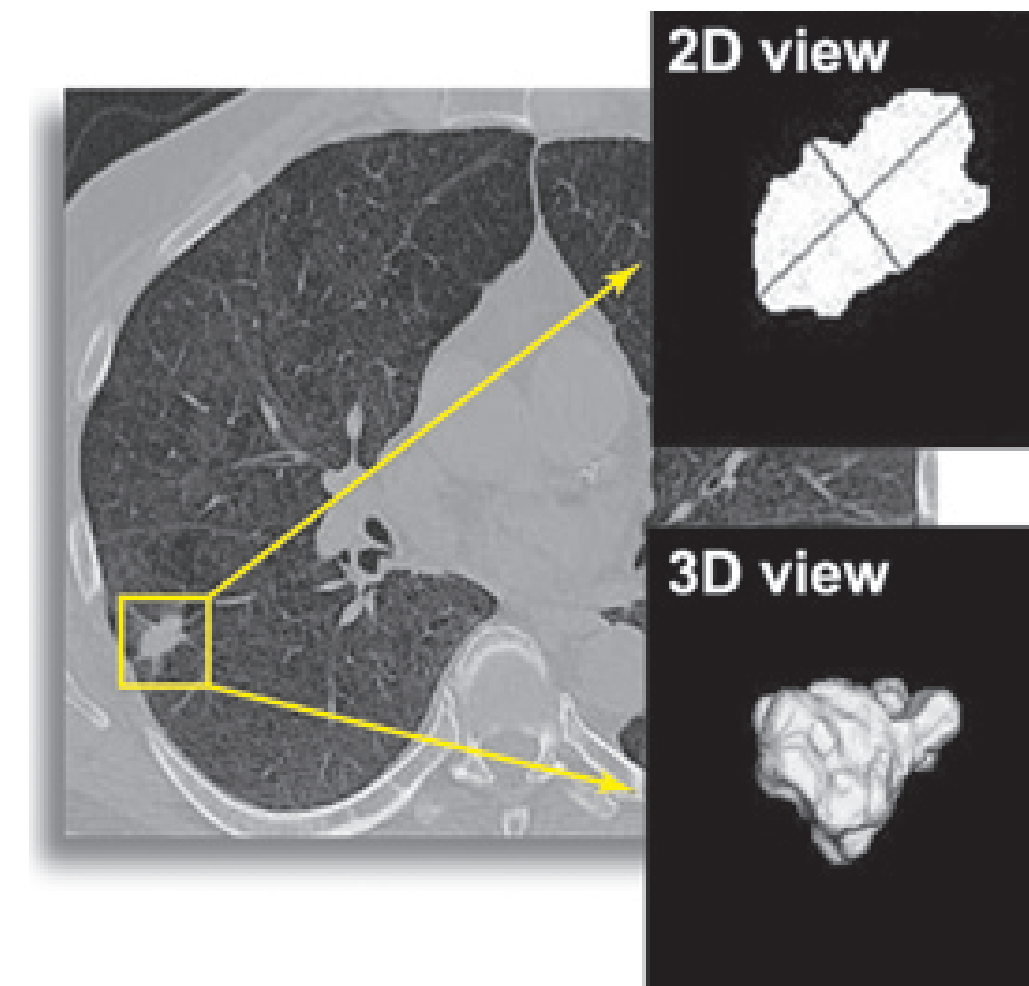
Long axis = 25.9 mm
Short axis = 19.8 mm
Volume = 4608 mm³

- Change in Long axis 4%
- Change in Volume 35%

Shows early progression which allows patients to select alternatives sooner and avoid toxicity when current treatment is futile.

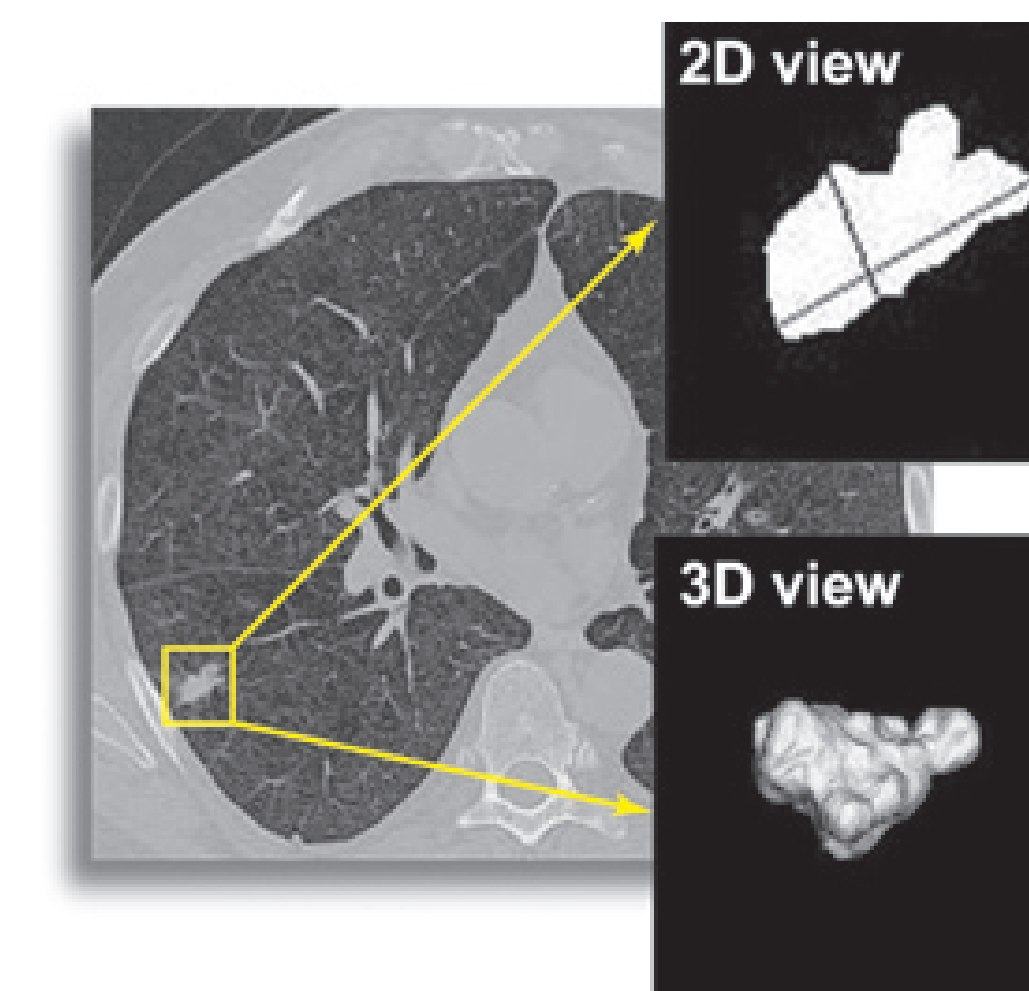
Volume Change

Pre Therapy



Long axis = 17.7 mm
Short axis = 9.6 mm
Volume = 886 mm³

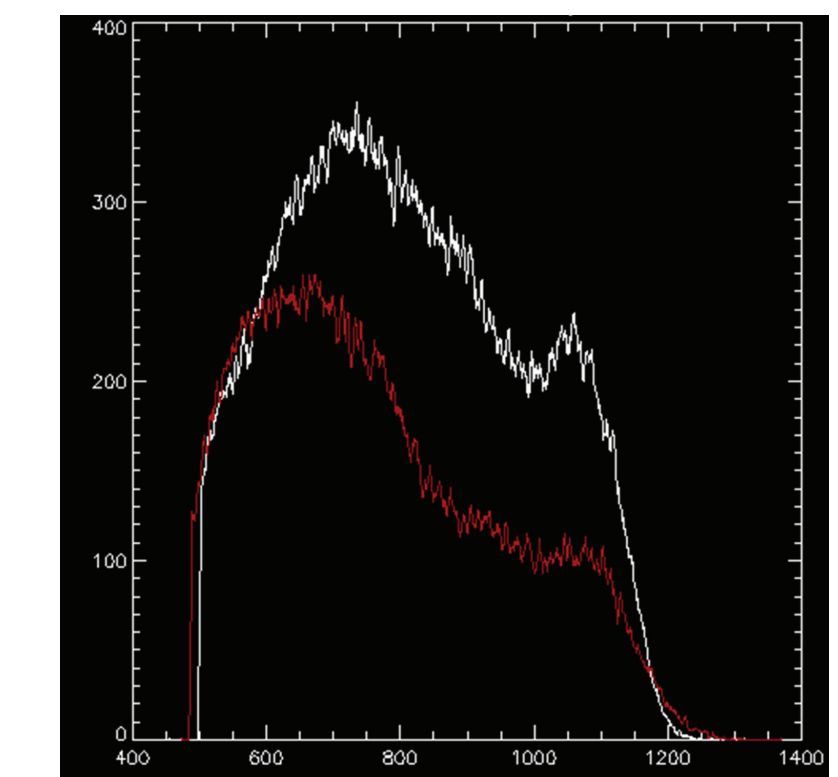
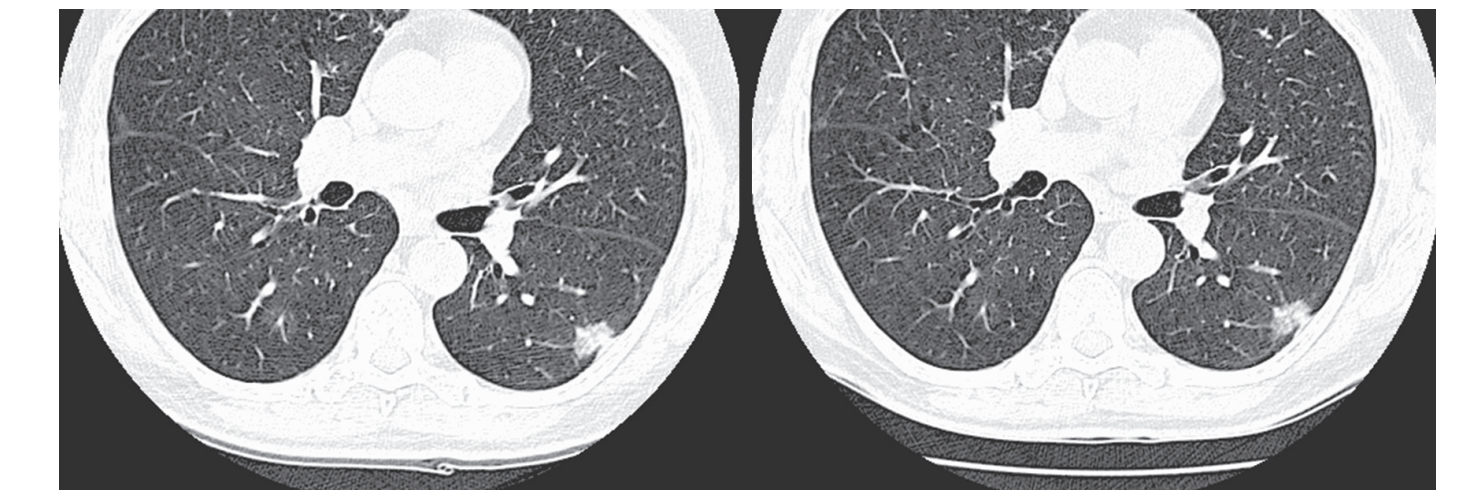
Post Therapy – 21 days



Long axis = 17.1 mm
Short axis = 7.4 mm
Volume = 525 mm³

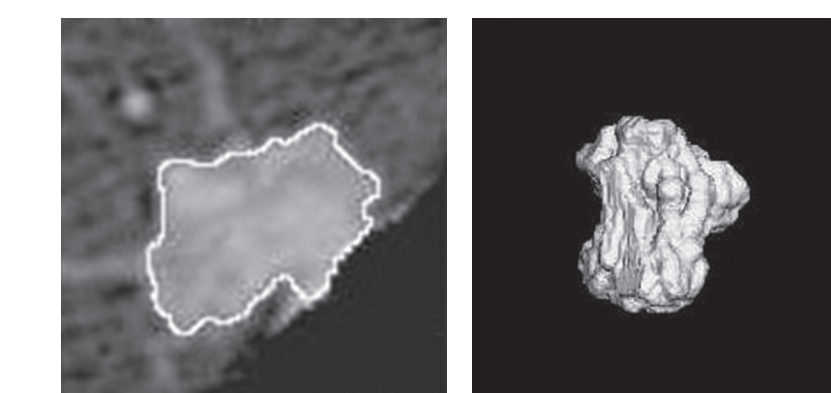
- Change in Long axis 3%
- Change in Volume 41%

Size and Density Change



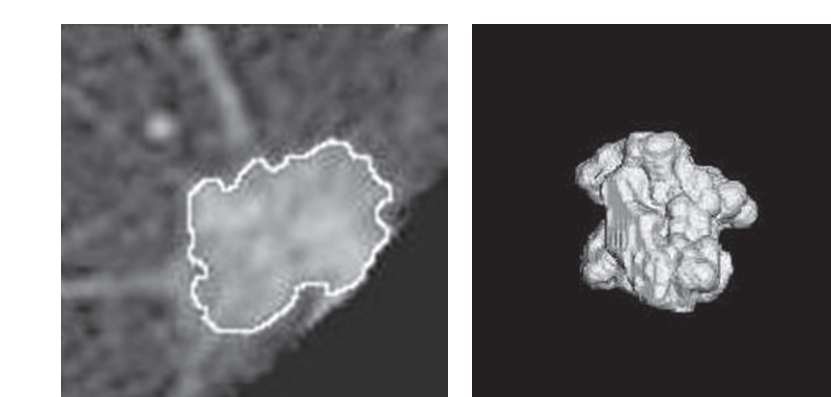
Pixel based density at baseline (white) and after 3 weeks of therapy (red). Note a decrease in the mean density as well as volume after a targeted therapy.

Baseline



Long axis = 18.3 mm
Short axis = 12.1 mm
Volume = 2585.8 mm³

Post Therapy – 1 month



Long axis = 17.5 mm
Short axis = 13.1 mm
Volume = 1740.1 mm³